

## Orthodontic Treatment in A Child With Crowded Teeth Using Myofunctional Appliance – A Case Report

Nurul Hajra Jahili<sup>1</sup>, Eka Erwansyah<sup>2</sup>

<sup>1</sup>Orthodontics Specialist Study Program, Faculty of Dentistry, Hasanuddin University, Makassar-Indonesia

<sup>2</sup>Department of Orthodontics, Faculty of Dentistry, Hasanuddin University, Makassar-Indonesia

### Abstract

**Introduction:** According to the World Health Organization (WHO) malocclusion is a defect or functional disorder that can be an obstacle to the physical and emotional health of patients who require treatment. Currently, the number of people with malocclusion reaches 80% of the total population in Indonesia while the case of crowded teeth is one of the oral health problems that are commonly found in Indonesia. The prevalence of crowded teeth reaches 80% and ranks third after caries and periodontal disease. Early treatment of malocclusions involving the teeth and skeletal system is an integral part of interceptive orthodontic treatment. **Case Report:** An 8-year-old patient came to Hasanuddin University Dental and Oral Hospital along with his parents with the main complaint of non-erupting anterior teeth. Intraoral examination revealed crowding of the maxillary and mandibular anterior teeth. Lateral cephalometric analysis showed class I skeletal. Interceptive orthodontic treatment was performed with myofunctional appliance with myobrace type. Initial staging was done with myobrace K1 for 4 months. The second stage was carried out with myobrace K2 for 4 months. The third stage is carried out with myobrace K3 for 4 months. The results of the treatment obtained anterior teeth in the normal arch and facial appearance improved. **Conclusion:** The maxillary and mandibular anterior teeth were corrected using myobrace appliance and obtained normal overjet and overbite, corrected mandibular anterior crowding and class 1 canine and molar relations.

**Keywords:** Crowded, interceptive orthodontic treatment, myobrace.

### INTRODUCTION

According to the World Health Organization (WHO) malocclusion is a defect or functional disorder that can be an obstacle to the physical and emotional health of patients who require treatment. Currently, the number of people with malocclusion reaches 80% of the total population in Indonesia while the case of crowded teeth is one of the oral health problems that are commonly found in Indonesia. The prevalence of crowded teeth reaches 80% and ranks third after caries and periodontal disease.<sup>1,2</sup>

One type of orthodontic treatment in children is interceptive orthodontics. This

treatment is performed when there are signs of malocclusion in the teeth of growing children. This treatment has the function of minimizing the impact of malocclusion, increasing confidence levels, and eliminating bad habits.<sup>1</sup>

Early treatment of malocclusions involving the teeth and skeletal system is an integral part of interceptive orthodontic treatment. The benefit of interceptive orthodontic treatment is that it corrects aberrant skeletal, dental, muscular and functional patterns. Myofunctional was developed with the aim. of improving dental and facial aesthetics in children aged 5-15 years. The myobrace device aims to correct functional abnormalities of the

stomatognathic system such as tongue position and function, abnormal nasal breathing patterns, and oral muscle tone, as well as tooth arrangement. This treatment not only corrects jaw relations but also corrects or eliminates bad habits that cause distorted facial and dental development.<sup>3,4</sup>

According to Moyers, a myofunctional appliance is a removable device designed to alter the neuromuscular surrounding the orofacial to enhance craniofacial bone development and/or growth. Meanwhile, according to White, Gardner, Leighton, functional devices utilize the natural forces they have and then pass on to the teeth and alveolar bone. Jasper jumpers, activators, bionators, twin blocks, and forsus are myofunctional appliance that accelerate mandibular growth. Although the success of therapy depends on patient compliance, many patients refuse these unpleasant myofunctional appliances.<sup>5</sup>

Myobrace was introduced by Myofunctional Research Company, Australia, followed by the rest of The Trainer System™ appliance in 2004. It consists of various devices for different age groups and comes in different sizes. Myobrace offers an alternative method of brace use that provides stable results, as it addresses one of the main causes of relapse, myofunctional habits.<sup>6,7</sup>

Myobrace can be used at any age, on mixed or permanent teeth. The ideal age is during eruption and in the final stages of mixed dentition. The longer the permanent teeth have been erupted, the less effective Myobrace will be.<sup>7,8</sup>

## DIAGNOSIS AND ETIOLOGY

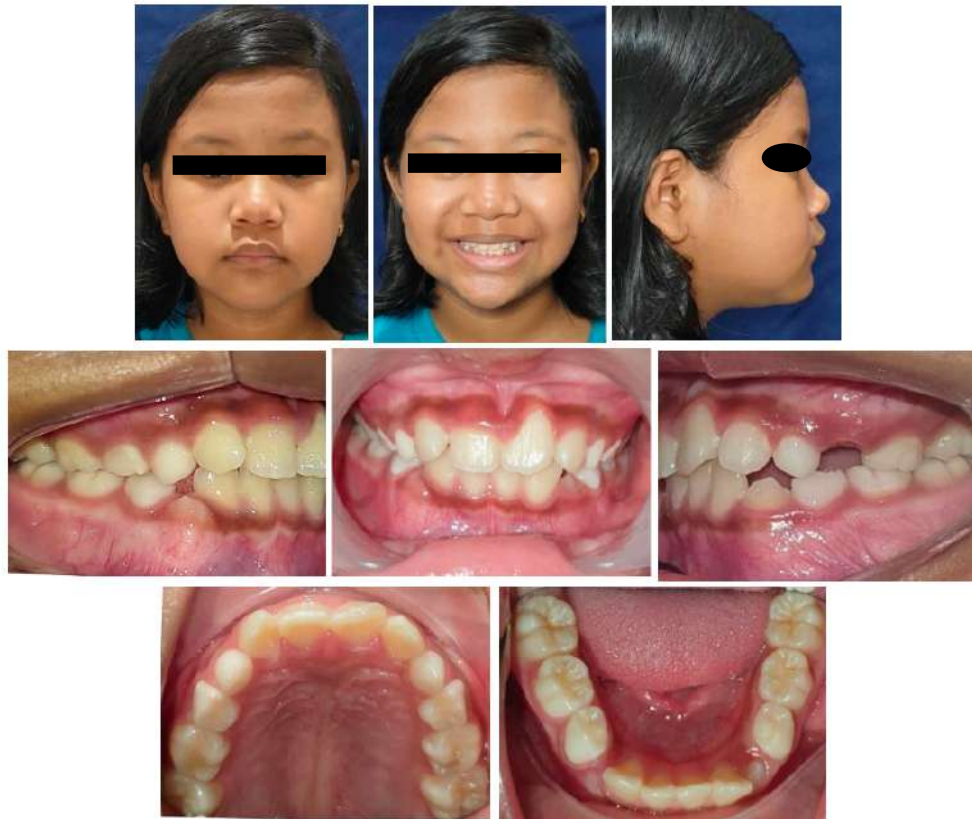An 8-year-old girl, escorted by her mother, came to Hasanuddin University Dental and Oral Hospital with complaints of crowding of upper and lower jaw anterior teeth. Extra oral

examination, normal and symmetrical face, convex profile. Intra oral examination showed that the second and third molar canines and premolars had not erupted, there was a narrowing of the space for the canines, the median line of the mandible shifted to the right by 1.5 mm, deep bite, maxillary and mandibular anterior teeth were crowded, first molar relation class 1.

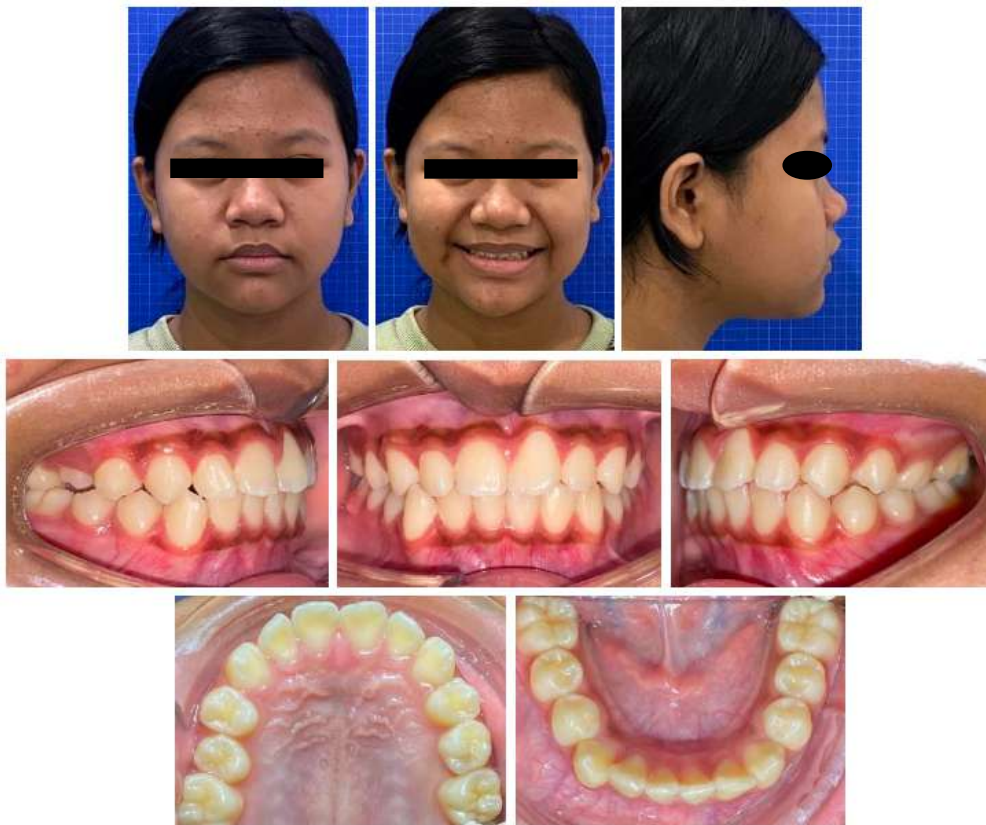Panoramic x-ray examination showed the canines, premolars had not erupted while the second and third molars were still in the developmental stage. Cephalometric analysis showed: SNA 82°, SNB 80° ANB 2°, I-Na 28°/6 mm, I-Nb 30°/4 mm; I-I:134° Occlusal-SN: 30°, Mandibular plane-SN: 22°, N-Pog: 4 mm. The diagnosis of this case was grade 1 dentoskeletal malocclusion, with crowded and median line of mandible shifted to the right 1.5 mm, deep bite The prognosis of the case was good as the patient was still in the growth stage. The patient was in the prepubertal growth period/Cervico Vertebrae Maturation Index (CVMI) stage 2. This is the optimal time for growth modification, and maximum growth response to the treatment given.

Alternative treatments in cases of crowded teeth in pediatric patients can be corrected using an expansion device to widen the jaw arch. The next treatment alternative is Myobrace which is the treatment option chosen by the patient's parents. The initial stage is carried out with myobrace K1 for 4 months. The second stage is carried out with myobrace K2 for 4 months. The third stage is done with myobrace K3 for 4 months.

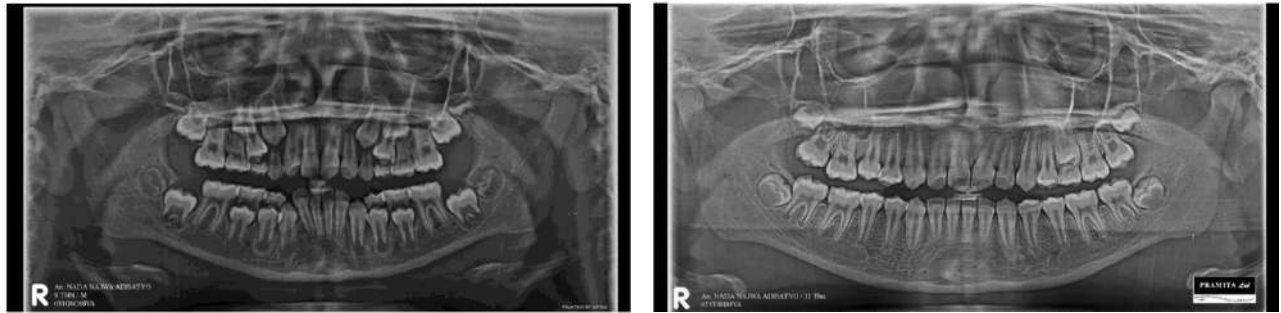The main goals of maxillary orthodontic treatment are to provide space for the eruption of the canines and premolars, correct the crowding of the anterior teeth and correct the patient's deepbite so that the lower facial height increases.



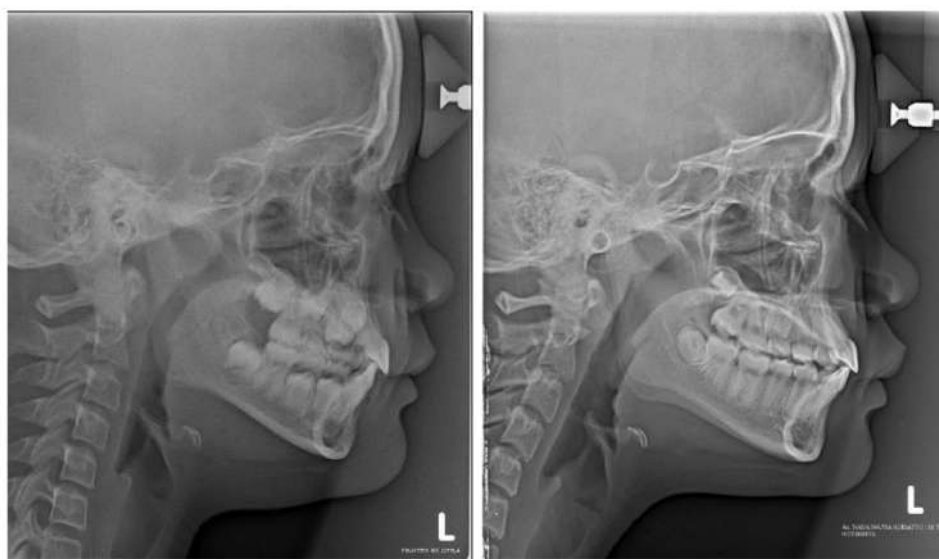**Fig 1.** Profile and intraoral photographs before treatment



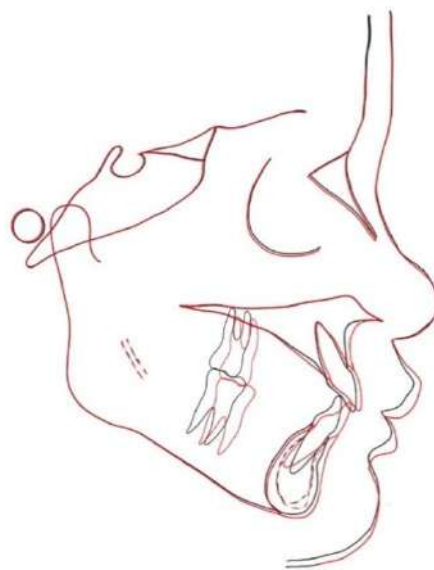
**Fig 2.** Profile and intraoral photographs after treatment



**Fig 3.** Panoramic radiographs before treatment (a) and after treatment (b)



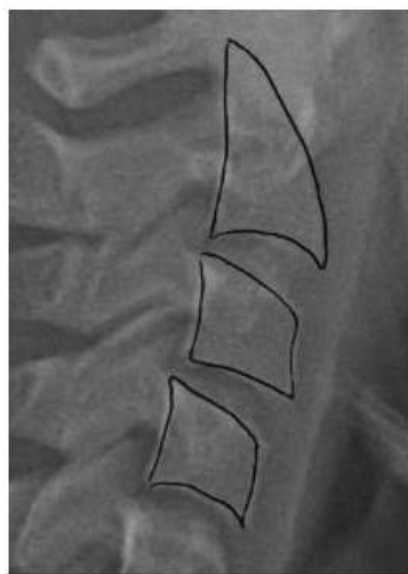**Fig 4.** Lateral cephalometry before treatment (a) and after treatment (b)



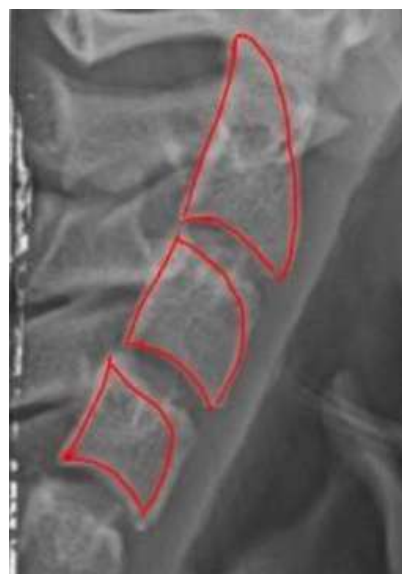
**Fig 5.** Lateral cephalometry before treatment (black line) and after treatment (red line)

Table 1. Cephalometric summary

Parameter	Norm (mean ± SD)	Pre-treatment	Post-treatment
<b>Cephalometric</b>			
SNA (°)	82 ± 2	82	83
SNB (°)	80 ± 2	80	81
ANB (°)	2 ± 2	2	2
U1-NA (mm)	4 ± 2	6	6
U1-NA (°)	22 ± 2	28	30
L1-NB (mm)	4 ± 2	4	5
L1-NB (°)	25 ± 2	30	31
Interincisal (°)	131 ± 2	134	129
E-Line to upper lip (mm)	2-3	0	1
E-Line to lower lip (mm)	1-2	2	1
Nasolabial (°)	102 ± 8	89	88



CS2, Kategori 1 (Stage Initiation)



CS2, Kategori 1 (Stage Initiation)

**CONCLUSION:** CS-2, the peak of mandibular growth that occurs on average 2 or 1 year after these stages respectively (Concavity at C2 Indicates the peak of growth is imminent)

**CONCLUSION:** CS-2, the peak of mandibular growth that occurs on average 2 or 1 year after these stages respectively (Concavity at C2 Indicates the peak of growth is imminent). This stage with 65-85% of juvenile growth remaining.

## DISCUSSION

Myofunctional bone growth modification appliance when used during the period of active growth in pediatric patients before or during puberty and stop disproportionate growth by redirecting the growth of the upper and lower jaws, includes a wide range of removable devices designed to affect the function and position of the mandible by altering the arrangement of muscles to redirect forces to the jaws, teeth and basal bone. Therefore, by changing the position of the mandible sagittally and vertically, muscle forces are produced, resulting in orthodontic and/or orthopedic changes.<sup>9</sup>

Myobrace is available for four stages of treatment, including habit correction, dental arch expansion, tooth alignment, and retention. The dynamore in myobrace helps to resist forces on the teeth by the buccinator muscle and orbicularis muscle which allows correction of misaligned teeth by providing a better arch shape. myobrace is available in a wide range of sizes for primary, mixed and permanent teeth.<sup>7</sup>

breathing patterns, oral muscle tone. Treatment with myobrace not only corrects jaw alignment but also corrects the disturbing bad habits that cause aberrant facial and dental development.<sup>4,8</sup>

Myobrace therapy aims to correct functional deviations of the stomatognathic system such as tongue position, abnormal

Thus the therapy tool has the following objectives:

- To improve nasal breathing.
- To retrain the muscle of the face and mouth.
- To correct a narrowed arch shape.
- To correct the arrangement of the teeth.

The The effectiveness of myobrace on the teeth and jaw arch by retraining the aberrant oral muscles, the resulting force is directed to the jaw which helps correct the narrow jaw arch and corrects the irregular arrangement of the teeth activated by the Frankel Cage which helps widen the jaw arch.<sup>4,8</sup>

Indications for treatment with myobrace are:

- Maloklusi klas II divisi 1
- Class II division 1 malocclusion
- Class II division 2 malocclusion
- Deep bite
- Open bite
- Crowding of teeth in the anterior regio

## CONCLUSION

Myobrace is a removable appliance that combines oral muscle rehabilitation with the properties of a dental positioner, acting on mouth breathing, faulty swallowing, and thumb sucking. Myobrace can be used in place of other myofunctional appliance. Myobrace corrects skeletal and dental discrepancies even in a short phase, but correction with fixed orthodontics may be required in some patients for finishing and detailing.

## REFERENCES

1. Empindonta S, Yusra Y. Hubungan antara kebutuhan perawatan ortodonti interseptif dengan tingkat pendidikan ibu. *J Kedokt Gigi Terpadu*. 2023;5(1):188-192. doi:10.25105/jkgt.v5i1.17086
2. Richter CH, Anindita PS, Kawengian SES. Hubungan antara Status Gizi dengan Gigi Berjejal pada Anak Usia 11 sampai 12 Tahun di SD Negeri 45 Manado. *e-GiGi*. 2021;9(2):152. doi:10.35790/eg.9.2.2021.33705
3. Hegde D, Das D, Mittal D. The Myobrace Appliance Therapy: Modus Operandi And Beyond: A Case Report. *IOSR J Dent Med Sci e-ISSN*. 2016;15(3):40-45. doi:10.9790/0853-1503084045
4. Fitriani Y, Puteri MM, Nelwan SC, Putri NMI. Myofunctional Therapy Using Twin Block Appliance in a Class II Malocclusion Patient with ADHD. *Acta Med Philipp*. 2022;56(8):82-86. doi:10.47895/amp.vi0.2773
5. Akhoun AB, Mushtaq M, Akhoun ZA. Section: Dentistry Myofunctional Appliances: An Overview. *Int J Contemp Med Res*. 2021;8(9):11-15. www.ijcmr.com
6. Paola da Cunha B, Desirée de JP, Monica Lage da C, Viviane de Andrade C de P. How the myobrace appliance works: Advantages and disadvantages. *J Dent Probl Solut*. 2021;8:019-023. doi:10.17352/2394-8418.000098
7. Aggarwal I, Wadhawan M, Dhir V. Myobrace: Say No to Traditional Braces. *Int J Oral Care Res*. 2016;4(239):82-85. doi:10.5005/jp-journals-10051-0019
8. Achmad H, Auliya N. Management of Malocclusion in Children Using Myobrace Appliance: A Systematic Review. *F1000Research*. 2024;13:53. doi:10.12688/f1000research.51879.1
9. et al. Removable Myofunctional Appliances : an Overview. *Int J Adv Res*. 2021;9(03):561-580. doi:10.21474/ijar01/12616